

## CUVS CLINICAL BRIEF

### FELINE SMALL CELL LYMPHOMA

Feline lymphoma is one of the most common types of cancer in cats and can be divided clinically and histopathologically into lymphocytic, low-grade, small cell lymphoma (SCLSA) or lymphoblastic, high-grade, large cell LSA (LCLSA). Along with inflammatory bowel disease (IBD), SCLSA is one of the more common causes of chronic gastrointestinal disease in cats. IBD and SCLSA are often indistinguishable based on clinical signs, routine blood work and ultrasonography. Biopsy, and sometimes additional testing, is required for definitive diagnosis.

#### Clinical Presentation

Cats with SCLSA can present with a variety of chronic gastrointestinal signs, including any combination of vomiting, diarrhea, appetite change, and weight loss. Physical examination may be within normal limits. The most common abnormalities include thickened or fluid-filled intestines and a thin body condition. Abdominal pain or inguinal alopecia are occasionally found.

#### Laboratory Findings

Routine blood tests are often within normal limits. Common abnormalities include a mild, non-regenerative anemia, a mature neutrophilia, and mild hypoalbuminemia. Occasionally, cats can have hyperglobulinemia due to mild polyclonal gammopathy; monoclonal gammopathy is rare. Hypoalbuminemia is rare in cats with IBD, so this finding should raise the suspicion for lymphoma (SCLSA or LCLSA).

Cobalamin (vitamin B12) deficiency is common in cats with chronic gastrointestinal disease, and may play a role in intestinal dysfunction. Cobalamin levels should be assessed in all cats with severe intestinal disease and in patients with SCLSA that are poorly responsive to therapy.

#### Imaging

Abdominal ultrasound is very useful for evaluating the GI tract, as well as other abdominal organs. Ultrasound can be normal with SCLSA, but commonly reveals thickening of the gastric and/or intestinal wall, particularly the muscularis layer. Enlarged and/or hypoechoic or enlarged mesenteric lymph nodes may also be seen. Importantly - ***it is not possible to distinguish IBD from SCLSA based on ultrasound findings.***

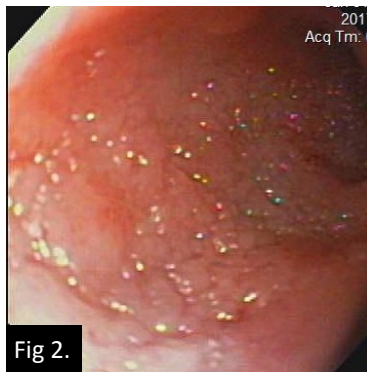
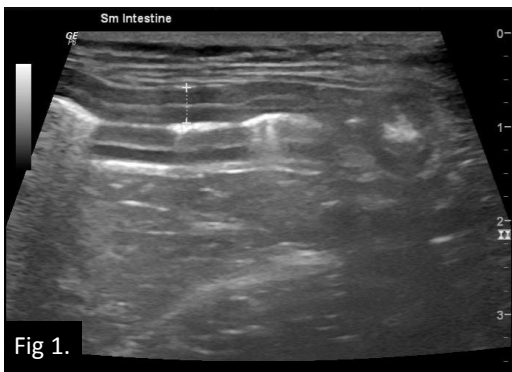

Fig.1. Ultrasonographic view of the intestines. Overall small intestinal wall thickness is increased at 0.38cm, with thickening of both the mucosal and muscularis layers.

Fig.2. Endoscopic view of the duodenum. The mucosa is thickened with a nodular/cobblestone appearance.

#### Biopsy and PARR testing

Biopsy is absolutely required for definitive diagnosis of SCLSA. Tissue samples can be obtained via endoscopy or via surgery. Benefits of ***endoscopic biopsy*** include the ability to: visualize mucosal lesions, enabling directed biopsy; collect multiple biopsies from each site; and to begin anti-inflammatory or chemotherapeutic agents without significant delay. Endoscopy is also less expensive and less invasive compared to surgery. Limitations of endoscopy are that biopsies are partial thickness, limited to the mucosa, and that endoscopy only enables access to some parts of the GI tract (stomach, duodenum, colon, and distal ileum). When endoscopy is performed, both upper and lower GI endoscopy are recommended to also enable ileal

biopsies (together with stomach and duodenum), as SCLSA may be present in the ileum alone. 6-8 biopsies should be collected from each site to optimize diagnostic yield.

Full-thickness *surgical biopsy* enables the collection of transmural samples of all segments of the GI tract in addition to biopsy of other organs (e.g., nodes, liver). Surgery is more invasive and expensive, and generally precludes the administration of anti-inflammatory or chemotherapeutic agents for at least 1 week post-operatively (ideally 10-14 days).

Even with histopathology, it can be extremely difficult to distinguish between IBD and SCLSA. Histologic features that aid in this differentiation include lymphoid infiltration of the deeper intestinal wall (beyond the mucosa), and increased intraepithelial lymphocyte numbers. Where histopathologic results are equivocal, polymerase chain reaction for antigen receptor rearrangement (PARR) should be used to test for clonal rearrangements in the lymphoid genome that occur in many cases of lymphoma. At CUVS, we perform PARR if the routine histopathology results are not diagnostic for SCLSA (even if the histopathology is interpreted as IBD). This practice has significantly increased our yield of positive diagnoses.

### Treatment

Standard treatment of SCLSA involves prednisolone in conjunction with chlorambucil, an alkylating agent which targets slowly dividing lymphocytes. *Prednisolone* is initiated at 2 mg/kg/day (generally 5 to 10 mg/cat/day given q24h, or divided q12h), and then reduced to 1 mg/kg/day once remission is achieved (usually after approx. 3-4 weeks). *Chlorambucil* is generally administered at 2 mg/cat PO every 48 hours in cats > 4kg, or every 72 hours in cats < 4kg). A bolus regimen (20 mg/m<sup>2</sup> PO q 14 days) is also described, and appears to result in a similar duration of clinical remission. Because chlorambucil can cause myelosuppression, regular monitoring of the CBC is recommended.

Cobalamin should be supplemented if deficiency is identified. Several supplementation protocols are described. A reasonable protocol is to administer B12 at 250 mg/cat for cats < 10 pounds, or at 400-500 mg/cat for cats > 10 pounds, given subcutaneously q7 days for 6 weeks, then q 14 days for 6 weeks. Maintenance therapy should be continued monthly in patients with persistent deficiency (defined as a serum cobalamin concentration < 500 measured at least 2 weeks after the last injection).

### Prognosis

*The prognosis for cats with SCLSA is generally favorable.* Almost all cats achieve remission, defined as improvement or resolution of clinical signs. Several studies suggest that 70%- 85% of cats with SCLSA will have a median survival of 1.5 to 2.5 years, and that survival times are longer in cats that achieve complete remission versus partial remission.



Jessica Chavkin, VMD, DACVIM (SAIM)

If you have questions about feline intestinal disease, or other internal medicine case, please do not hesitate to call one of our internists, Monday through Saturday. **203.595.2777**



880 Canal Street, Stamford, CT 06902

[www.cuvs.org](http://www.cuvs.org)